

# Veterinary Forensics

## for prosecution:

# Best & Worst practices

Dr. Alessia Mariacher

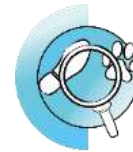DVM, post-graduate scholarship holder at  
**National Reference Centre for Veterinary Forensic Medicine**  
Istituto Zooprofilattico delle Regioni Lazio e Toscana "M. Aleandri"  
Grosseto – ITALY  
tel. +39-0564-456249  
e-mail: [alessia.mariacher@izslt.it](mailto:alessia.mariacher@izslt.it)





Istituto Zooprofilattico Sperimentale  
del Lazio e della Toscana *M. Aleandri*

## National Reference Centre for Veterinary Forensic Medicine



CeMedForVet

Centro di Referenza Nazionale  
per la Medicina Forense Veterinaria

- CeMedForVet was established by decree of the Italian Ministry of Health in 2009, at the Istituto Zooprofilattico Sperimentale of Lazio e Toscana
- IZS are public health institutions that work for animal health and food safety in the context of **national public health system**
- CeMedForVet provides technical and scientific support to the judicial authority and police, to investigate criminal acts against animals



Malicious  
poisoning

Forensic  
pathology

Forensic  
genetics

Ce Med  
For Vet



Professional  
training

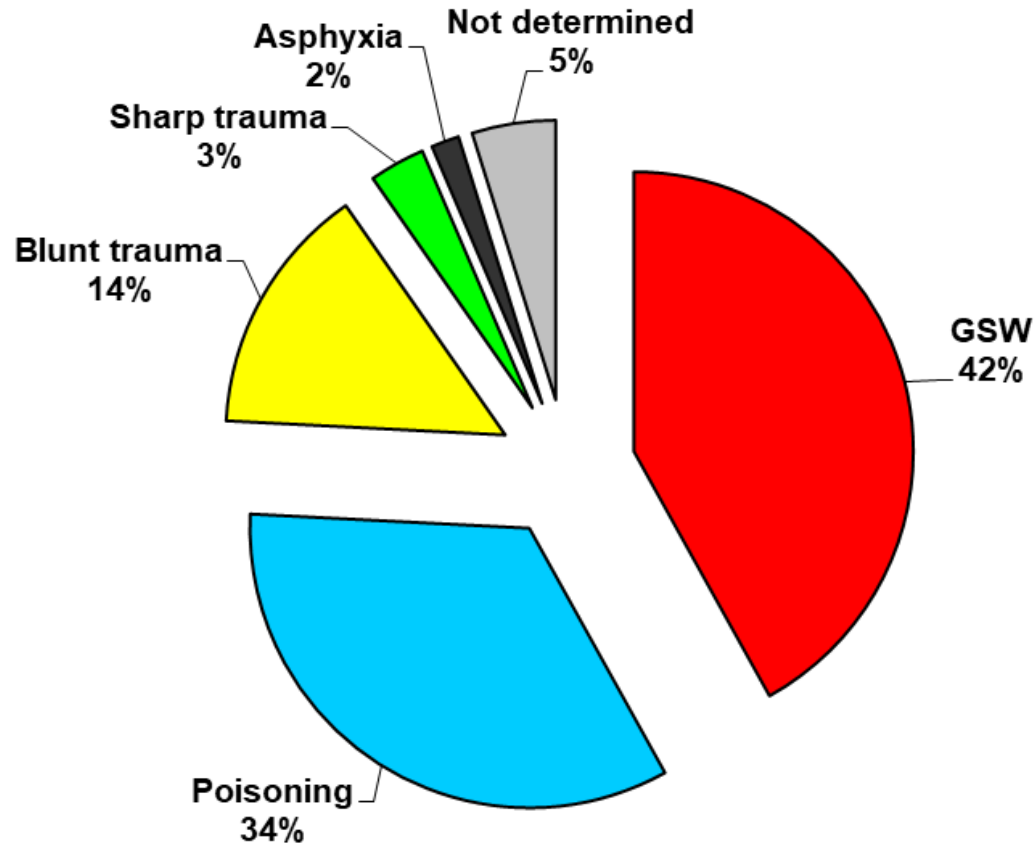


MIAH



<b>ACTIVITIES 2010 – 2017</b>	
<b>Poisoning cases</b>	<b>899</b>
<b>Forensic necropsies</b>	<b>829</b>
<b>Forensic DNA analysis</b>	<b>3.627</b>
<b>Technical advisory in criminal proceedings</b>	<b>182</b>
<b>Professional training courses</b>	<b>123</b>
<b>Peer-reviewed publications</b>	<b>23</b>
<b>Invited speakers at national/international congresses</b>	<b>32</b>
<b>National or international research projects</b>	<b>5</b>
<b>Agreements with public bodies</b>	<b>5</b>
<b>Published manuals</b>	<b>5</b>
<b>International proficiency testing</b>	<b>1</b>

# POACHING 2010 – 2018







**VICTIMS**



**CRIME SCENES**



**SUSPECT**

# Veterinary forensics begins... at the crime scene



Identification of CS itself



Effective and safe processing of CS



Right questions = Useful evidence



Chain of custody + Trace integrity



Appropriate (vet) forensic analysis and  
reporting



 Accurate and fair criminal justice





## Major issues at the CS from a veterinary perspective

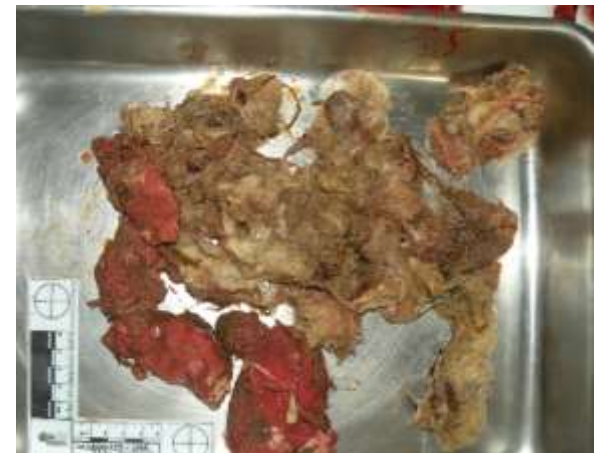### 1. Not recognizing the crime scene

Usually stems from police prejudging the event as non-suspicious.  
Most common mistake: pick up the body and take it to 'a vet' (if any).

Consequences:

- scene not sealed nor processed
- undermined search for a primary scene
- lack of photographic documentation
- loss of evidence on the scene





## ZnP poisoning



Identification of CS itself



Effective and safe processing of CS

Right questions = Useful evidence

Chain of custody + Trace integrity

Appropriate (vet) forensic analysis and reporting

 Accurate and fair criminal justice





## Major issues at the CS from a veterinary perspective

### 2. Inappropriate processing of CS involving dead animals

Usually stems from lack of specific training of first responders.  
Most common mistakes: underestimate health risks + underestimate potential of veterinary forensic analyses.

Consequences: - failure to use personal protective equipment  
- failure to seek standard forensic analysis for each individual carcass found (at least X-ray + necroscopy)







## First report of *Mycobacterium bovis* infection in a free-ranging Marsican brown bear

Rosario Fico<sup>1</sup>\*, Alessia Mariacher<sup>1</sup>, Erika Ciancetta<sup>1</sup>, Clelia Elmi<sup>1</sup>, Alessia Franco<sup>1</sup>, Antonio Battisti<sup>1</sup>

<sup>1</sup> Istituto Zooprofilattico Sperimentale della Regione Lazio in Roma - Via Salaria 1316, 00158 Roma, Italy

### INTRODUCTION

An adult female Marsican brown bear (*Ursus arctos marsicanus*) died in Abruzzo in 2014. The carcase was subjected to forensic necropsy to ascertain the cause of death and to rule out illegal killing (poaching, poisoning). A presumptive diagnosis of mycobacterial infection was made based on gross findings, histopathology and microbiology confirmed a diagnosis of *Mycobacterium bovis* infection. *M. bovis*, causative agent of bovine tuberculosis, has a wide host range and is often maintained in complex transmission cycles [1]. Diagnosis of tuberculosis in wildlife uses histology, histopathology and microbiology [2]. *M. bovis* was previously cultured from pooled lymph nodes of a black bear (*U. americanus*) in the absence of lesions [3]. To the authors' knowledge this is the first report of *M. bovis* infection and associated lesions in a free-ranging brown bear.

### MATERIALS AND METHODS

A full necropsy was performed. Tissue samples for histology were formalin-fixed, embedded in paraffin, sectioned at 4 µm and stained with hematoxylin–Eosin (HE) and Ziehl–Neelsen (ZN). Samples were submitted to culture for bacterial pathogens including Mycobacteria. Bacterial identification was obtained by molecular techniques (PCR, sequencing) of selected target genes.

### RESULTS

#### Necropsy

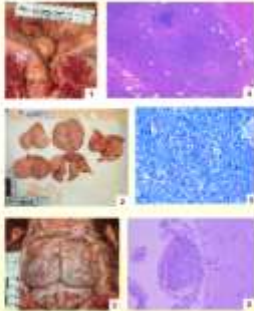
Gross findings in the abdominal cavity included peritonitis, mild peritoneal effusion, massively enlarged mesenteric mesenteric lymph nodes (1–2), thickening of intestinal wall and hepatosplenomegaly.

Lesions of respiratory tract included membranous catarrhal exudate, pulmonary oedema and suppurative pneumonia.

After skull opening, meningitis hyperemia was observed (3).

#### Microbiology

Slow-growing *Mycobacterium* sp., identified as *M. bovis* by molecular methods, was isolated from multiple organs (intestine, mesenteric lymph nodes, liver, spleen, lung and kidney). *Staphylococcus schweitzeri* subsp. *copulorum* was isolated from mesenteric (4) and peritoneal fluid.



#### Histopathology

Inflammation with large necrotic foci was observed in the peritoneum and intestinal mucosa (4), along with massive necrosis of mesenteric lymph nodes, granulomatous hepatitis, membranoproliferative glomerulonephritis and granulomatous meningitis (5). Acid-fast bacilli (3) were observed both in macrophages and extracellularly in all the examined organs (skin, lymph nodes, liver, spleen, intestine, peritoneum, kidney, lung, myocardium and aorta/aorta).

#### Figure legends:

- 1 Lesions of intestine wall and adjacent lymph node
- 2 Mesenteric lymph nodes, cut surface
- 3 Meningitis hyperemia
- 4 Poor organized granulomas and necrosis in the intestinal wall (HE, 15x)
- 5 Acid-fast bacilli in mesenteric lymph node (ZN, 85x)
- 6 Granulomatous meningitis (H&E, 20x)



Identification of CS itself



Effective and safe processing of CS



Right questions = Useful evidence



Chain of custody + Trace integrity



Appropriate (vet) forensic analysis and reporting



Accurate and fair criminal justice







## Major issues at the CS from a veterinary perspective

### 3. Lack of evidence collection

Usually stems from lack of specific training of first responders.  
Most common mistake: right questions are not asked of the evidence at hand.

Consequences:

- loss of ballistic evidence
- loss of potential substrates for chemical analysis (e.g. faeces or vomit on the scene)
- loss of entomological evidence





Identification of CS itself



Effective and safe processing of CS



Right questions = Useful evidence



Chain of custody + Trace integrity



Appropriate (vet) forensic analysis and reporting



Accurate and fair criminal justice





## Major issues - after CSI - from a veterinary perspective

### 4. Impaired chain of custody and trace integrity

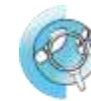Usually stems from underestimation of crimes against animals.

Most common mistake: failure to comply with the provisions of the code of criminal procedure, especially in cases where suspects are known.

Consequences: - time & money waste for forensic analyses on evidence that will likely be inadmissible in court  
- impaired trial



Istituto Zooprofilattico Sperimentale  
del Lazio e della Toscana *M. Aleandri*



CeMedForVet

Centro di Referenza Nazionale  
per la Medicina Forense Veterinaria





Identification of CS itself



Effective and safe processing of CS



Right questions = Useful evidence



Chain of custody + Trace integrity



Appropriate (vet) forensic analysis and reporting



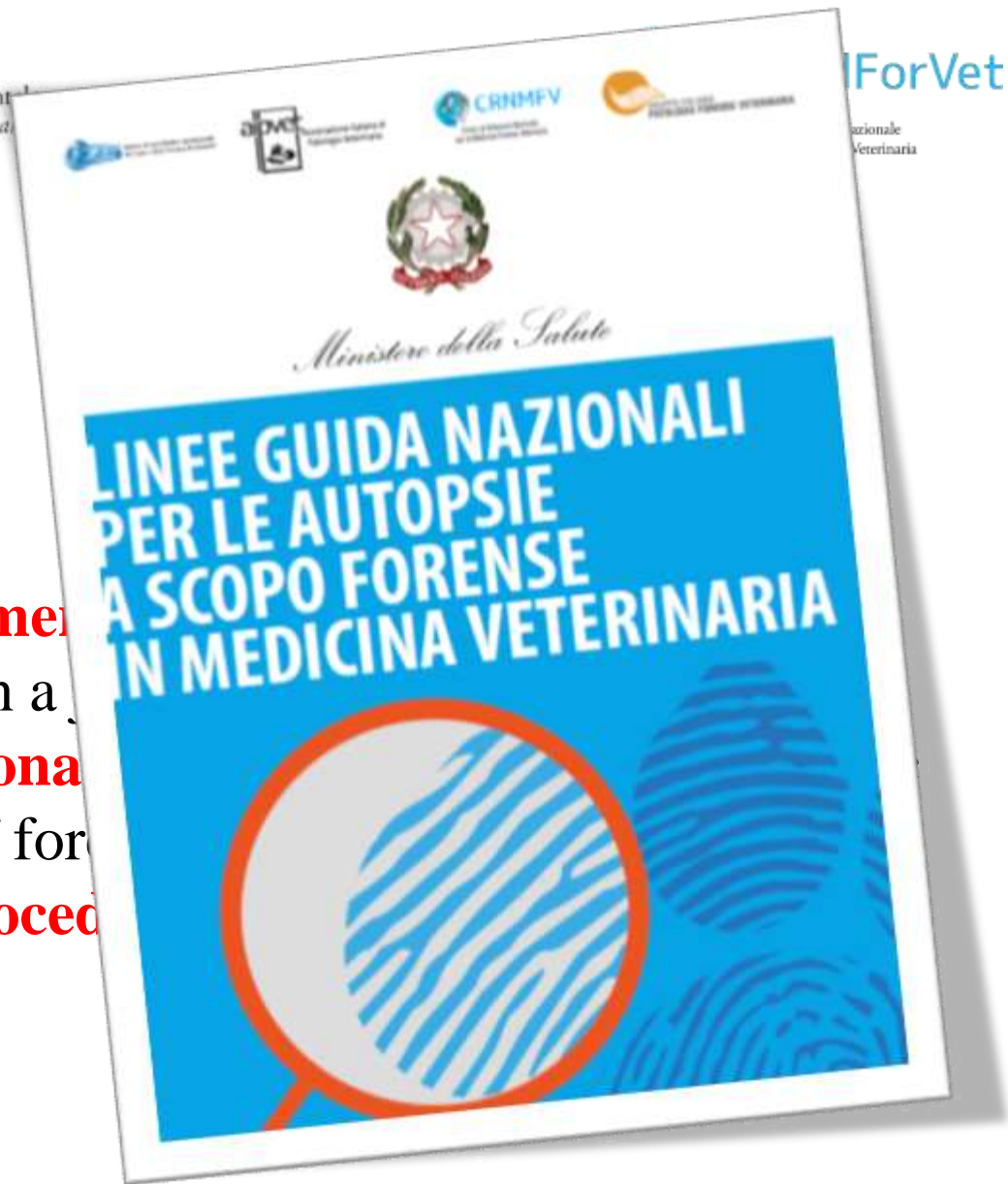Accurate and fair criminal justice







5. **Incorrect appointment** (auxiliary rather than a...)
6. **Unskilled professional** (necropsy *instead* of for...)
7. **Lack of official procedure** (published soon)



# Forensic Veterinary Necropsy

- Can answer questions about: cause of death, manner of death, post-mortem interval, any other NAI, ...
- Compliance with code of criminal procedure + chain of custody + trace integrity

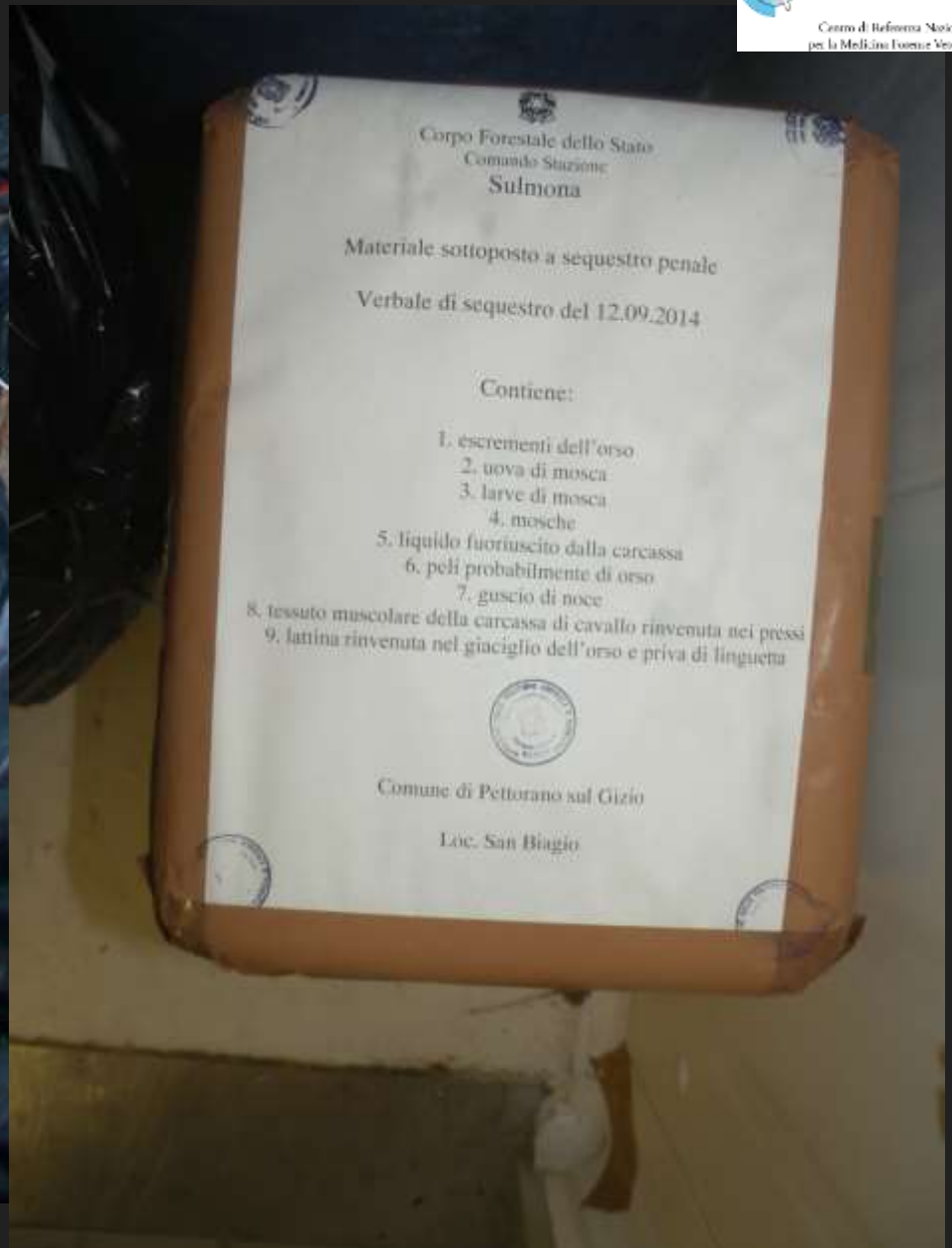
## Forensic Veterinary Necropsy

- Unambiguous and certain identification of the samples (carcass, baits, or other evidence)
- Includes thorough photographic documentation with metric reference, complete skinning of the carcass, skull opening, careful inspection of gastrointestinal contents (both macro- and micro-scopic)
- **May acquire new evidence and/or assign evidence to other labs** (toxicology, histology, entomology, ballistics, botany, geology, ...)



# Marsican brown bear found dead















NR 14068681  
Data 16.09.2014  
Specie ORSO BRUNO

ISTIS  
Istituto Peritalopatologico  
Sperimentale delle Regioni  
Lazio e Toscana



14068681  
ORSO BRUNO



I  
14068681

J  
14068681

K  
14068681

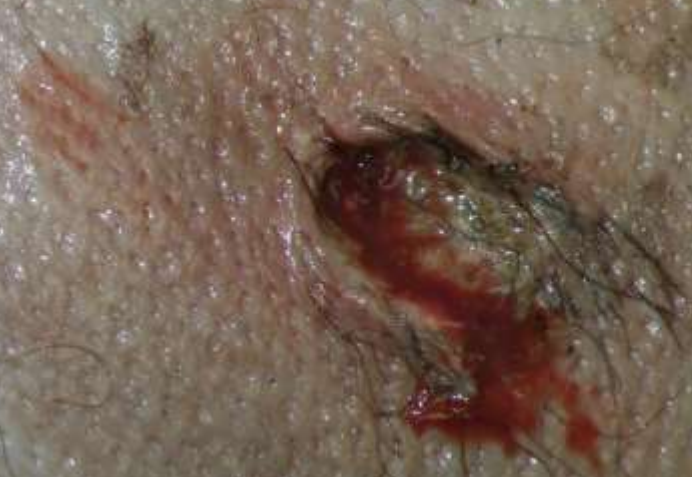M  
14068681

L  
14068681

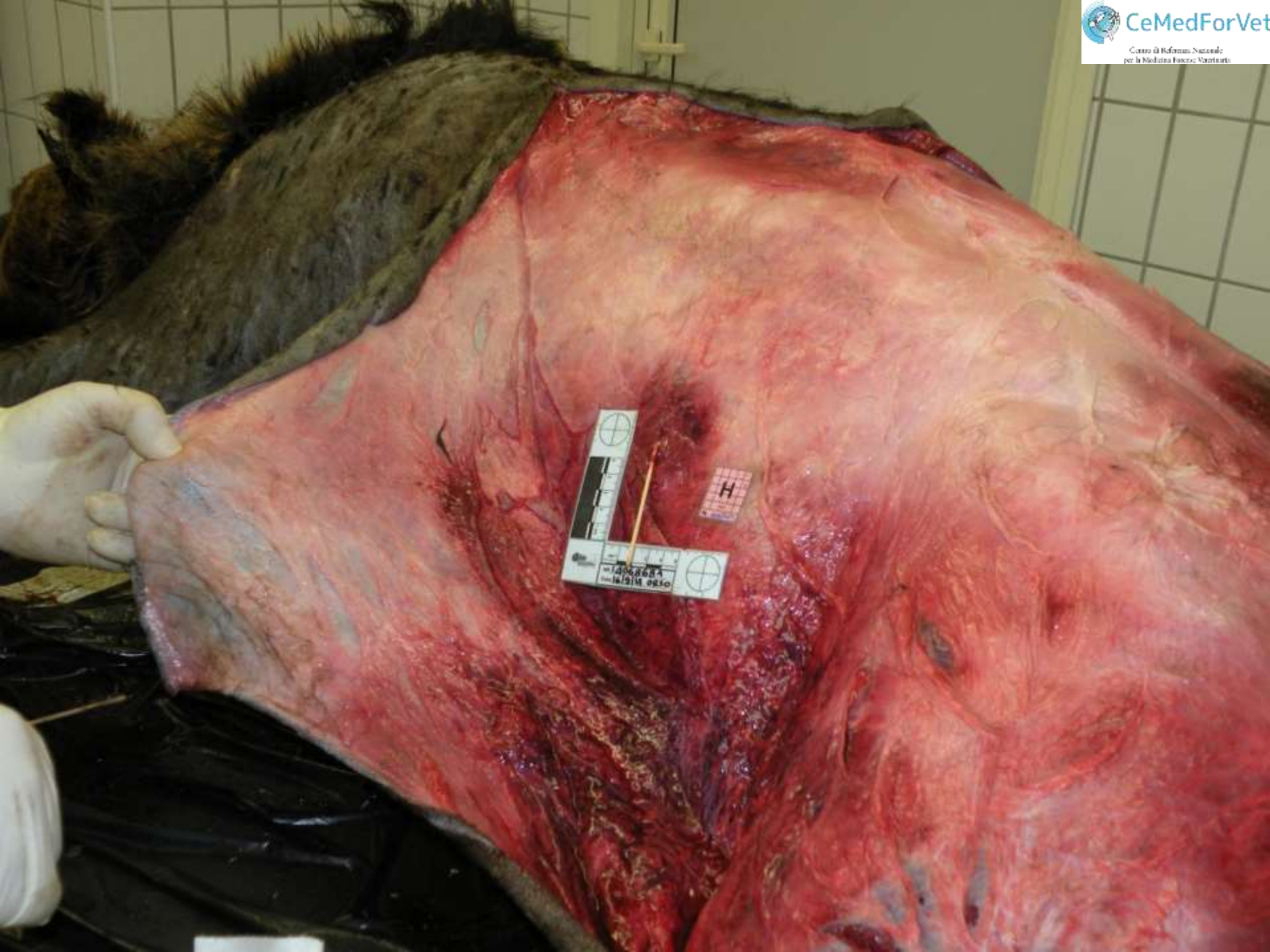N  
14068681

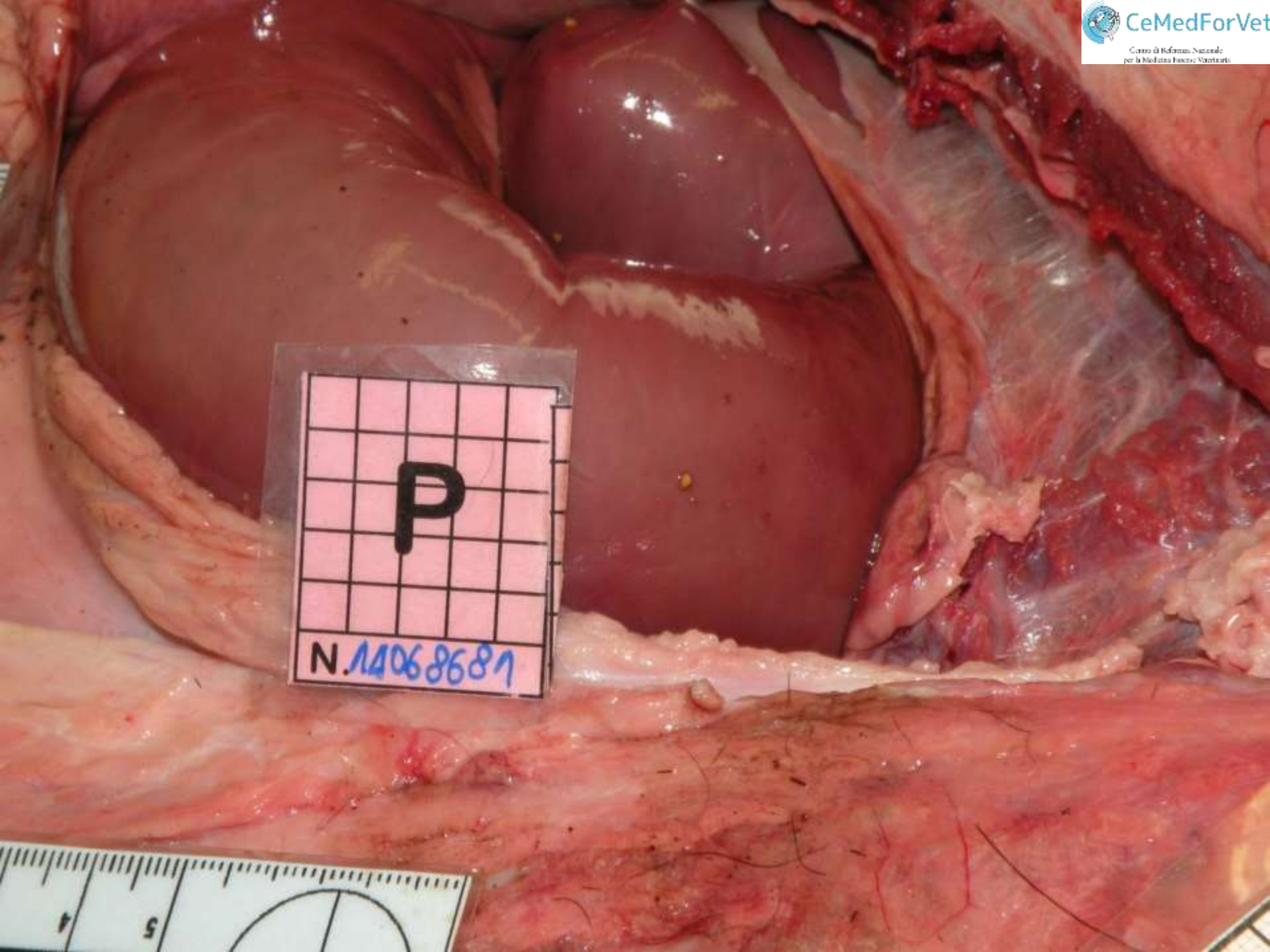








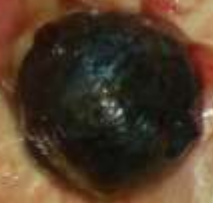




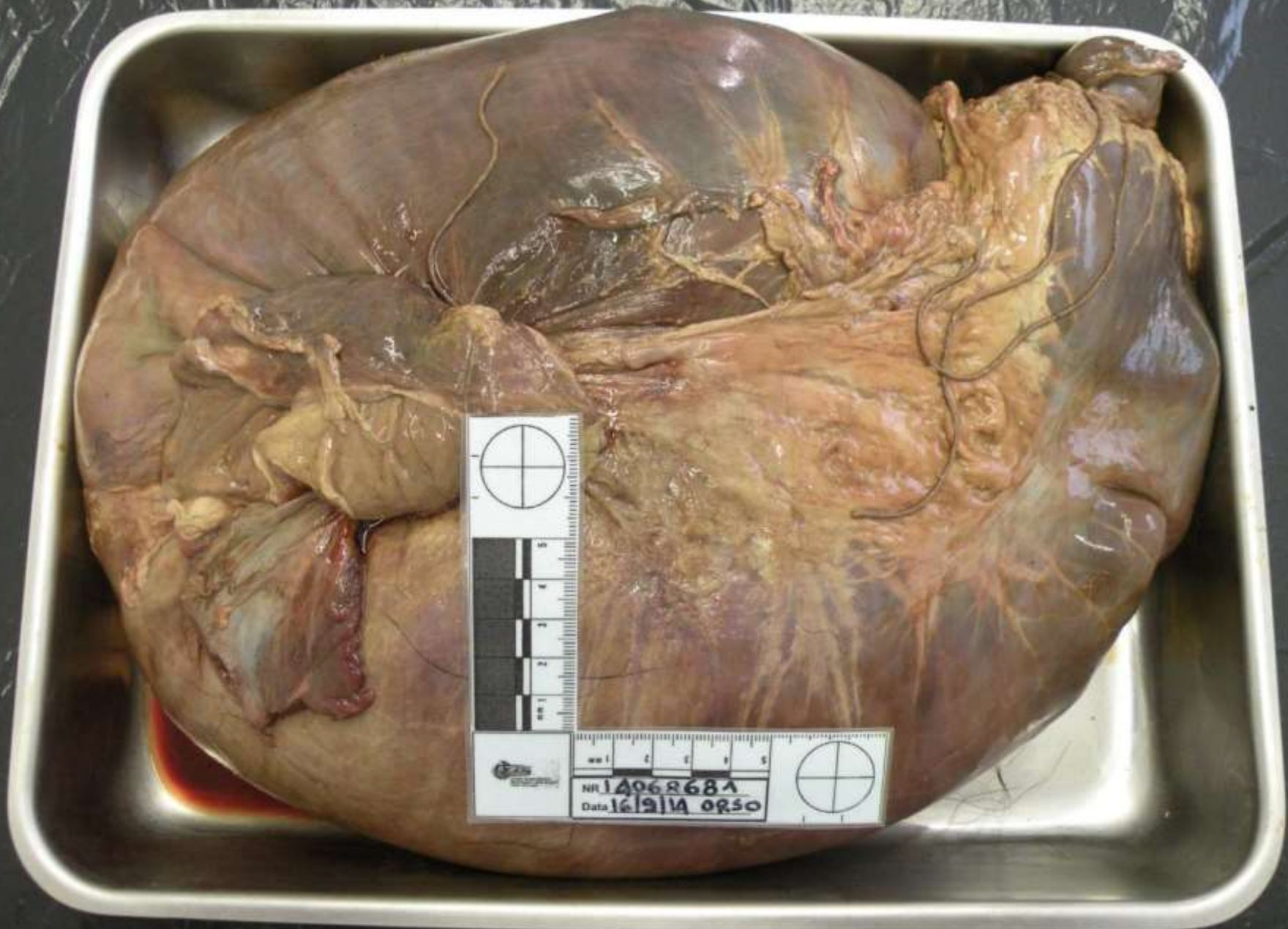
P  
N.14068681



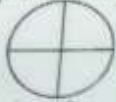







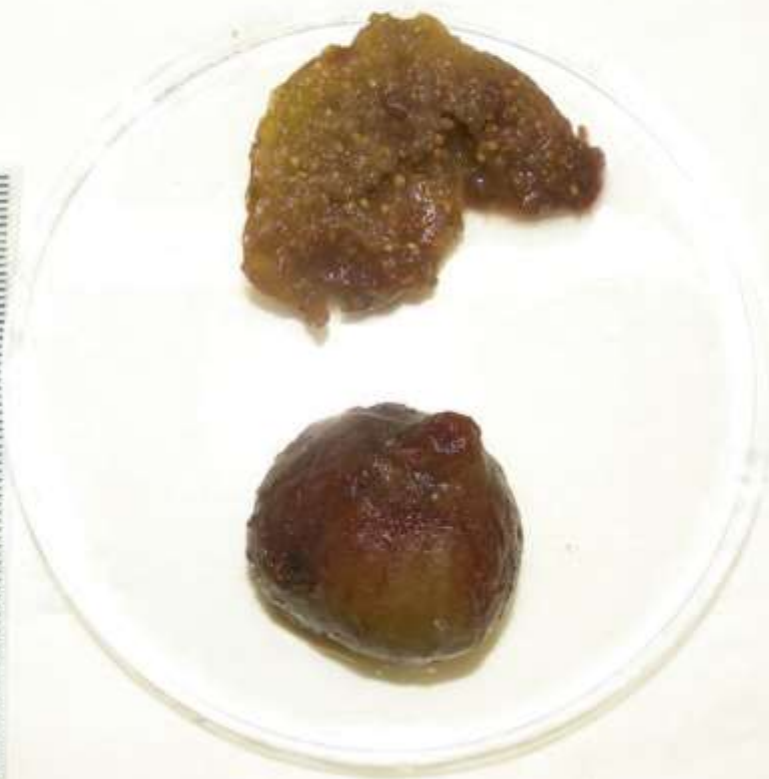mm 1 2 3 4 5  
NF 14068684  
Data 16/9/14 orso








NR 14068681  
Data 16/9/14 orso



A1  
N. 14068681



NR 14068681 ORSO  
Data 17-9-14



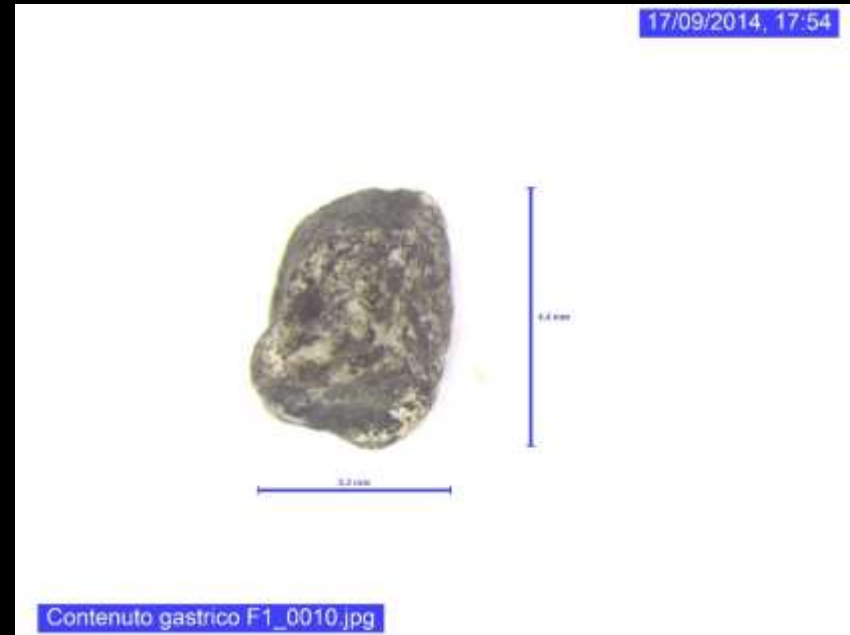

17/09/2014, 17:43



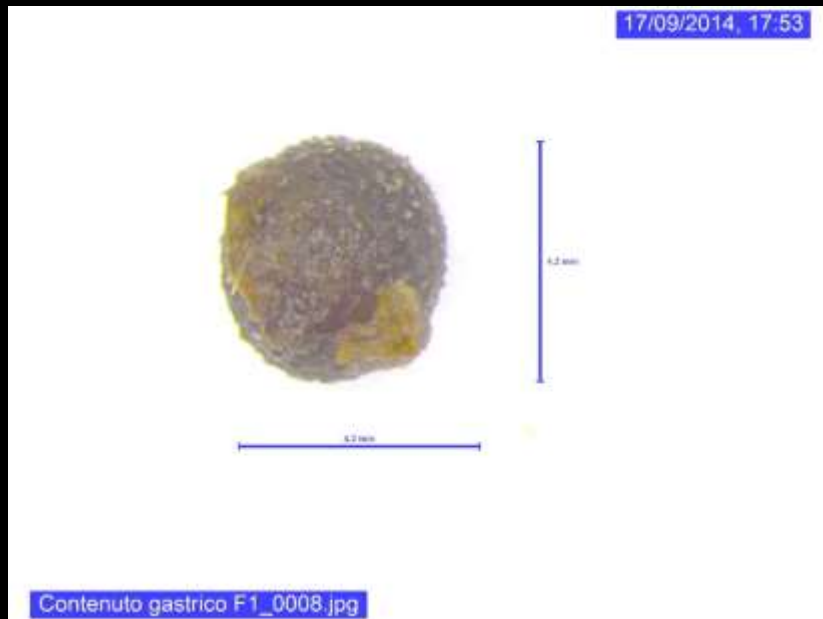Contenuto gastrico F1.jpg

17/09/2014, 17:54



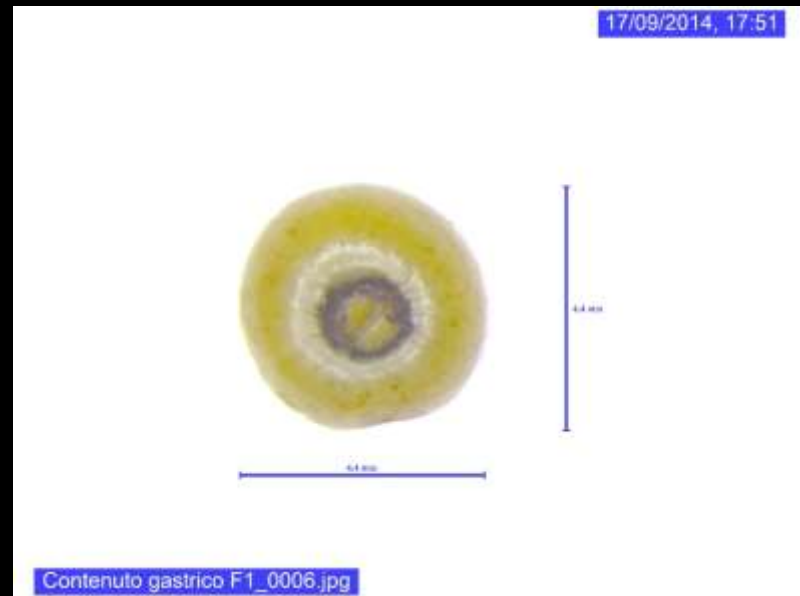
Contenuto gastrico F1\_0010.jpg

17/09/2014, 17:53

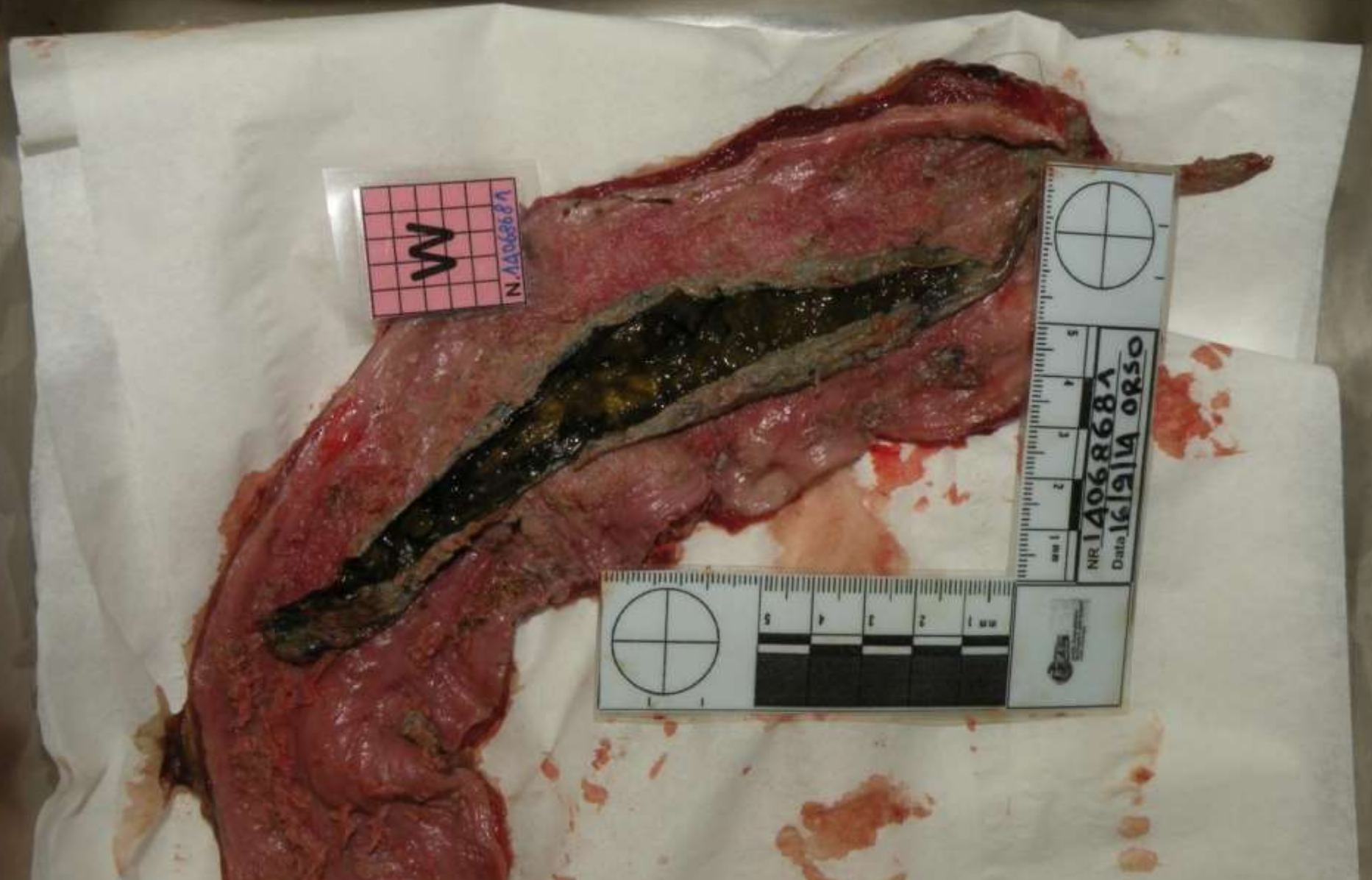

Contenuto gastrico F1\_0008.jpg

17/09/2014, 17:51



Contenuto gastrico F1\_0006.jpg



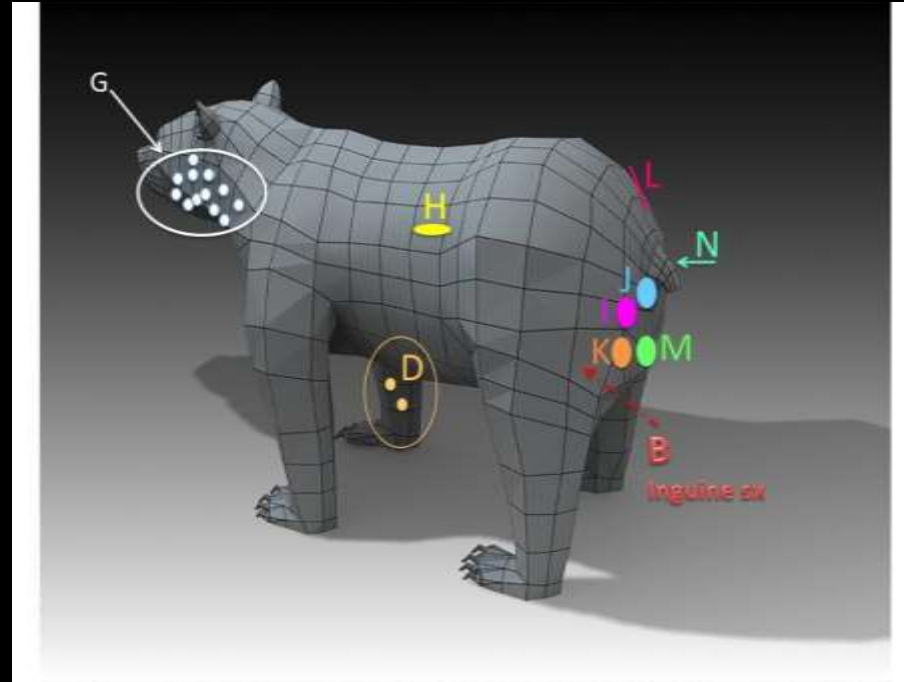
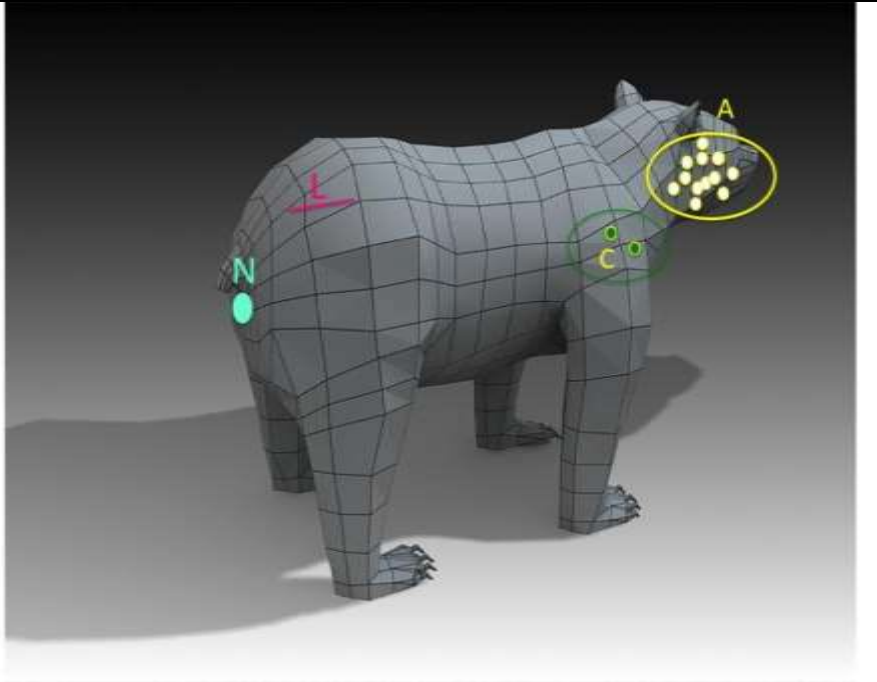
W  
N. 1406868A

1 2 3 4 5  
cm

1 2 3 4 5  
cm

NR 1406868A  
Data 16/9/14 ORSO





The bear died from **acute peritonitis due to intestinal rupture caused by shotgun wounds** to the back of the body (lesions H to M).

GSW found on the front of the body (lesions A, C, G) were due to a shotgun loaded with smaller sized pellets. The presence of a scarred rim, dated the lesions before the fatal shot.

Therefore **the bear had been shot twice**: a first time a few days before his death with a shotgun, probably while the bear was standing on his hind legs facing the shooter, and a second time with a shotgun loaded with larger pellets, while the bear was walking away from the shooter.

**Death occurred a few hours after being hit** due to an acute peritonitis caused by intestinal lesions.

The finding in the stomach of elements related to domestic poultry species allowed to link the criminal event to an aggression by the bear to a **henhouse**, whose location was already known to the **local press** a few days before the discovery of the carcass of the bear.



## Orso ucciso in Abruzzo con una fucilata, indagato confessa: "Sono stato io"

*Antonio Centofanti, operaio di 57 anni, la settimana scorsa era rimasto ferito dopo un incontro ravvicinato con un orso. Wwf lancia allarme: "13 animali morti in 4 anni, va potenziata la task-force"*

di GIUSEPPE CAPORALE



19 settembre 2014



## What to expect from the technical report

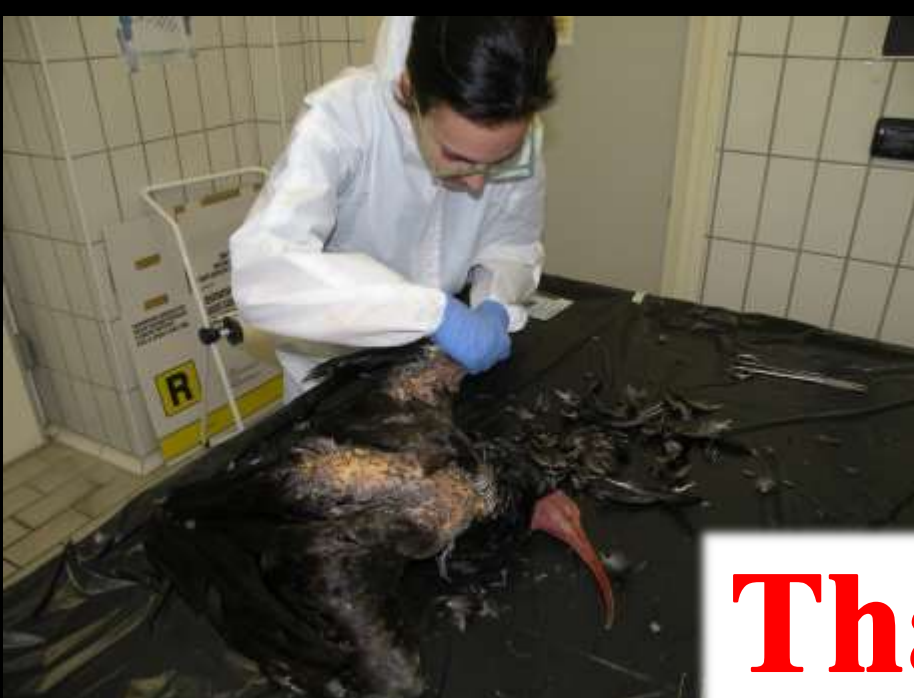
- Must accurately describe what has been done
- Must not be ambiguous and must clearly answer the specific questions posed by judicial authority/police
- Conclusions must be supported by all necessary information and appropriate references
- The report should highlight any other criminally relevant element, thus it is potentially able to trigger the start of a new proceeding

## New perspectives in veterinary forensics

- Search for human DNA from animal carcasses or objects on the scene, even in case of adverse weather conditions (McLeish et al, 2018)
- Use of unusual substrates for chemical-toxicological analysis (Richards et al, 2015 & 2017)
- Criminalistic approach to poisoning events (environmental criminology and situational prevention of poaching, profiling of ‘serial poisoners’, risk maps with hot-spots, etc)

**These future developments will not be possible without the strictest respect of good investigation practices, both on the scene and in the forensic lab**





**Thank  
you**

Contact:

**Dr. Rosario Fico**  
Head of National Reference Centre  
for Veterinary Forensic Medicine  
Istituto Zooprofilattico delle Regioni  
Lazio e Toscana "M. Aleandri"  
Grosseto – ITALY  
tel. +39-0564-456249  
e-mail: [rosario.fico@izslt.it](mailto:rosario.fico@izslt.it)

